

TRABAJO PRÁCTICO #7: TEMA GENERAL

1. Observá con atención las siguientes ilustraciones y escribí en español el tema general de cada una, es decir, respondé a la pregunta ¿de qué trata la ilustración?

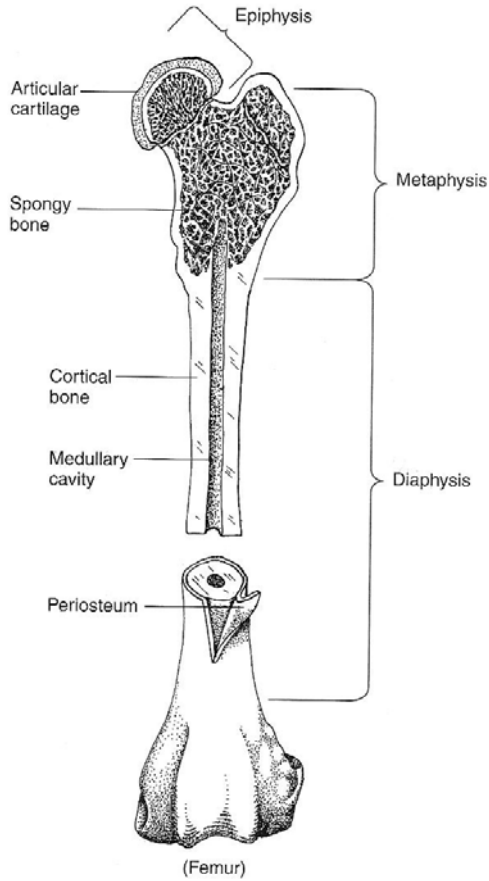


Ilustración 1. Tema:

Fuente: Christenson, D. *Veterinary Medical Terminology*, W. B. Saunders 1997, p. 82

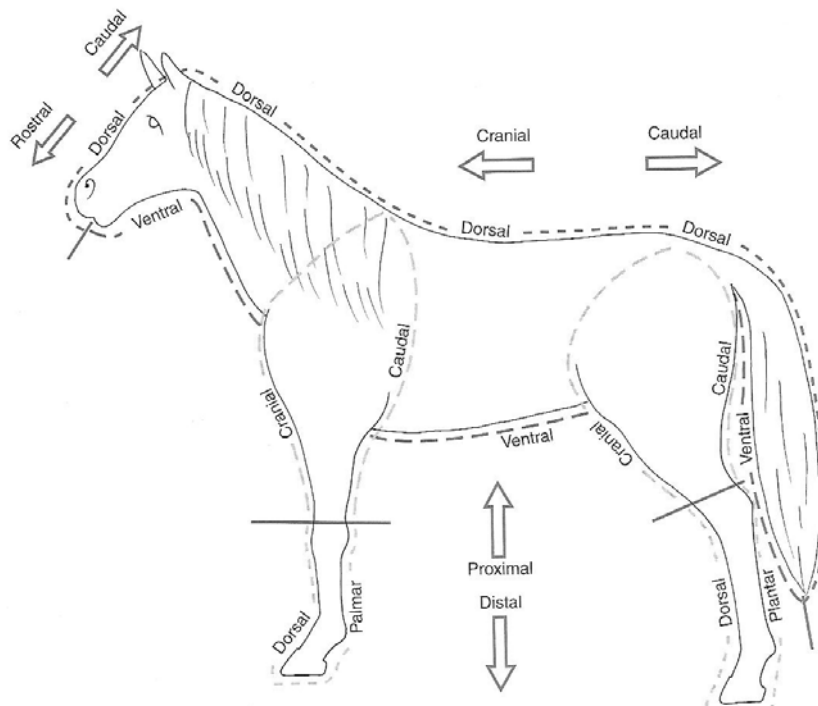


Ilustración 2.
Tema:

Fuente: Christenson, D. *Veterinary Medical Terminology*, W. B. Saunders 1997, p. 10

2. Observá los datos mencionados en las siguientes tablas y la manera en que se hallan relacionados, y escribí en español el tema general de cada una, es decir, respondé a la pregunta ¿de qué trata cada tabla?

Tabla 1: Tema general: _____

Figure 4-3: USDA quality grade chart

Degree of Marbling:	Maturity:				
	A	B	C	D	E
Slightly abundant	PRIME				
Moderate			COMMERCIAL		
Modest	CHOICE				
Small					
Slight	SELECT		UTILITY		
Traces					
Practically Devoid	STANDARD			CUTTER	

Fuente: *Tennessee Master Beef Producer Manual*, Agricultural Extension Service. The University of Tennessee.

Nota: "USDA" significa "United States Department of Agriculture"

Tabla 2: Tema General: _____

Table 2: Japan: Imports of Pacific and Atlantic Salmons (Fresh & Chilled) in 1992		
Country	Quantity (Kg)	Value (US\$)
Norway	5 161 240	47 111 320
Denmark	169	2 371
United Kingdom	560 633	5 506 557
Canada	1 174 079	9 480 582
USA	462 402	4 951 323
Australia	1 444 166	15 390 951
New Zealand	763 379	5 603 474
Chile	1 027 851	10 101 688
Russia	133 123	82 137
Iceland	1 452	13 595
Total	10 728 494	98 243 998
Source: Fishery Statistics of Japan (1992), Statistics and Information Dept., Ministry of Agriculture, Forestry and Fisheries, Japan.		

Fuente: Revista *INFOFISH International* Abril 1995

3. Leé los siguientes textos breves y escribí el Tema General de los mismos en una o pocas palabras en español, a manera de título, siempre respondiendo a la pregunta ¿de qué trata cada texto?

Texto 1: Tema General: _____

Blood supplies cells with water, electrolytes, nutrients, and hormones, and removes waste products. The cellular elements supply oxygen (red blood cells), protect against foreign organisms and antigens (white cells), and initiate coagulation (platelets). Because of the diversity of the hematopoietic system, its diseases are best discussed from a functional point of view. Function may be classified as normal responses to abnormal situations (e.g. leukocytosis and left shift in response to inflammation) or primary abnormalities of the hematopoietic system (e.g. pancytopenia from marrow failure). Moreover, abnormalities may be quantitative (i.e. too many or too few cells) or qualitative (i.e. abnormalities in function).

Fuente: **The Merck Veterinary Manual**, Merck & Co. Inc., 1998, pág. 3.

Texto 2: Tema General: _____

Broadly speaking, resistance to parasitic infections falls into two categories. The first of these, often termed innate resistance, includes species resistance, age resistance, and in some cases breed resistance which are not immunological in origin. The second category, acquired immunity, is dependent on antigenic stimulation, and subsequent humoral and cellular responses. Although, for reasons explained below, there are few vaccines available against parasitic diseases, natural expression of acquired immunity plays a highly significant role in protecting animals against infections and in modulating the epidemiology of many parasitic diseases.

Fuente: Urquhart, G. M., Armour J., Duncan, J. L., Dunn, A. M., Jennings, F. W., **Veterinary Parasitology**, Blackwell Science, 1996, pag. 263.

Texto 3: Tema General: _____

The primary functions of the GI tract include prehension of feed and water, mastication, ensalivation, and swallowing of feed; digestion of feed and absorption of nutrients; maintenance of fluid and electrolyte balance; and evacuation of waste products. There are four primary functions –digestion, absorption, motility and evacuation- and, correspondingly, four primary modes of dysfunction.

Normal GI tract motility involves peristalsis, muscle activity that moves ingesta from the esophagus to the rectum; segmentation movements, which churn and mix the ingesta; and segmental resistance and sphincter tone, which retard aboral progression of gut content. In ruminants, these movements are of major importance in normal forestomach functions.

Fuente: **The Merck Veterinary Manual**, Merck & Co. Inc., 1998, pag. 109.

Texto 4: Tema General: _____

Endocrine glands are collections of specialized cells that synthesize, store and release their secretions directly into the bloodstream. They respond to changes in the internal and external environments to coordinate activities that maintain homeostasis. Endocrine secretions are proteins, polypeptides, steroids, catecholamines, or iodothyronine hormones that are transported by the blood to influence the functional activity of target cells elsewhere in the body. Other populations of cells are concerned with degradation of hormone after it has exerted its physiologic function. Degradation is accomplished by peptidases on the cell surface, by lysosomal enzymes after uptake by cells, and by excretion in the bile or urine, after conjugation with glucuronide or sulphate. Endocrine glands are small compared with other body organs, they are richly supplied with blood, and there is a close anatomical relationship between endocrine cells and the capillary network.

Fuente: **The Merck Veterinary Manual**, Merck & Co. Inc., 1998, pag. 380.

Texto 5: Tema General: _____

There are two ovaries in the cow: one on the right and one on the left side, which produce the egg or ova and the female sex hormone, estrogen. At each estrus, a blister-like structure, called a follicle, enlarges and ruptures approximately 14 hours after the end of heat. This ruptured follicle releases the egg and the funnel of the oviduct picks it up. It is here that the sperm cell and egg unite to form the embryo which develops into the calf. The embryo enters the uterus four days after breeding and secretions from the uterus nourish it until 35 days when the membranes of the embryo and uterus unite to complete implantation. There are two oviducts and two uterine horns plus a single cervix which is about two or three inches long and one inch in diameter. The cervix is cartilaginous and hard tissue with three well developed rings on the inner lining and forms an effective seal during pregnancy. The cervix opens up or dilates during heat so sperm can pass to the uterus and an insemination tube can be inserted during and shortly after estrus. The vagina forms a passageway from the outside vulva to the cervix where the semen is deposited during natural service. The vulva is seen from the outside and increases in vascularity and size during heat.

Texto 6: Tema General: _____

Damage to components of the nervous system may occur as a result of trauma or disease. Depending on the cause and severity of the damage, the resultant effects may range from minor sensory loss to death. Severed nerves cannot regenerate. However, if a portion of a nerve remains intact it may be possible for it to repair itself. Such repair takes a long time. The damaged nerve may never again provide completely normal transmission, but it may provide for functional use of the affected body part that it innervates.

One of the most common traumatic spinal cord injuries in dogs occurs because of rupture of one or more of the intervertebral discs. The intervertebral discs lie between the vertebral bodies, ventral to the vertebral canal and the spinal cord. The discs are composed of two different types of tissue. The outer portion (thick shell) of the disc is made of layers of a type of fibrous, cartilaginous, connective tissue. The center of the disc contains a gelatinous substance. The discs are designed to absorb the compressive forces placed on the spinal column. Unfortunately, the design of the discs is flawed. The cartilage portion of the discs is thin on the dorsal border. Deterioration of the discs, due to age or disease, weakens this already weak link. Now, with even the normal force generated by jumping off of a chair, the gelatinous center of the deteriorating disc may not be contained, and it bulges or ruptures through the weak dorsal border. This compresses the spinal cord dorsally against the vertebral bone. The length of time post-injury, the degree of compression of the spinal cord, and the ensuing myelitis determine the degree of paresis or paralysis present in the patient. The onset of clinical signs with protrusion of an intervertebral disc may be very sudden (acute), or progressive. The first thing an owner might notice is ataxia in his or her pet. Rupture of cervical discs usually results in tetraplegia. Rupture of discs in the caudal thoracic area usually results in paraplegia. Sometimes protrusion of the disc material is unilateral in the canal, exerting pressure on the spinal nerve roots and ganglia. This may result in monoparesis or hemiplegia. Myelography is generally used to isolate the specific disc(s) involved. The prognosis of a paralyzed patient depends on the length of time post-injury and the degree of analgesia present, particularly in the extremities. For example, a paraplegic animal is tested for superficial pain and possibly deep pain in the hindlimbs. A mild painful stimulus is applied to the toes (i.e., a toe pinch). If the patient responds to the mild pain, his prognosis is good; the afferent tracts to the brain are still functional. If, however, a patient shows signs of complete analgesia when tested for both superficial and deep pain shortly after the injury, his prognosis is poor. Prompt surgical intervention to decompress the spinal cord in areas of disc protrusion, along with medications to reduce inflammation, may restore a paralyzed patient's mobility. No guarantees can be made. The recovery period for these patients is typically quite long. Owner patience and cooperation are important during the recovery period.

Fuente: Christenson, Dawn E., **Veterinary Medical Terminology**, W. B. Saunders Company, (1997), pags. 168-169.